

Nordic Claw Atlas

Definitions of claw diagnoses



A collaboration between Nordic claw health experts

Nordic Claw Atlas

The Nordic Claw Atlas is a collection of photos showing the disorders that can be recorded by use of the common Nordic Claw Health Recording Program.

The atlas contains written trait definitions of all the diagnosis that leading claw experts from Denmark, Finland, Norway and Sweden has agreed upon.

All trait names are shown in English, Danish, Finnish, Norwegian and Swedish.



Produced in August 2013.

Photos are taken by:

Professor Christer Bergsten, SLU, Biosystem and technology

Associate professor DVM Nynne Capion, KU.SUND

Mogens Christensen

Associate professor Terje Fjeldaas, NVH, Department of Production Animal Clinical Sciences

Dicipline Specialist Åse Margrethe Sogstad, TINE/Cattle Health Services

Phd Maren Knappe-Poindecker, NVH, Department of Production Animal Clinical Sciences

Herd health veterinarian Reijo Junni, Environmental Health Office of Central Ostrobothnia

Special thanks to:

Christer Bergsten, SLU, Biosystem and technology

Karin Ulvshammar, Växa Sverige

Elina Paakala, Faba co-op

Terhi Vahlsten, Faba co-op

Licentiate Veterinary Medicine Jouni Niemi

Herd health veterinarian Reijo Junni, Environmental Health Office of Central Ostrobothnia

Doctor of Veterinary Medicine Minna Kujala

Pia Nielsen, Knowledge Centre for Agriculture

Nynne Capion, KU.SUND

Gert Pedersen Aamand, Nordic Cattle Genetic Evaluation

Terje Fjeldaas, NVH, Department of Production Animal Clinical Sciences

Åse Margrethe Sogstad, TINE/Cattle Health Services

Maren Knappe-Poindecker, NVH, Department of Production Animal Clinical Sciences

for helping coordinating the work and translating the text.

Contents

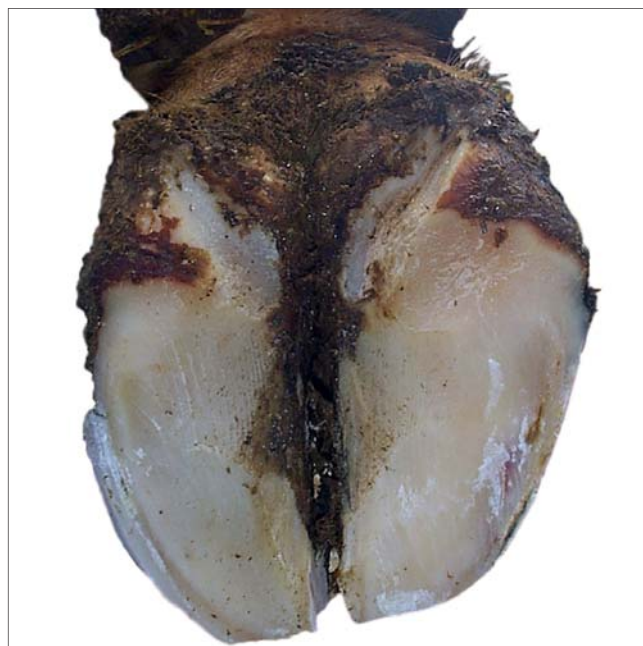
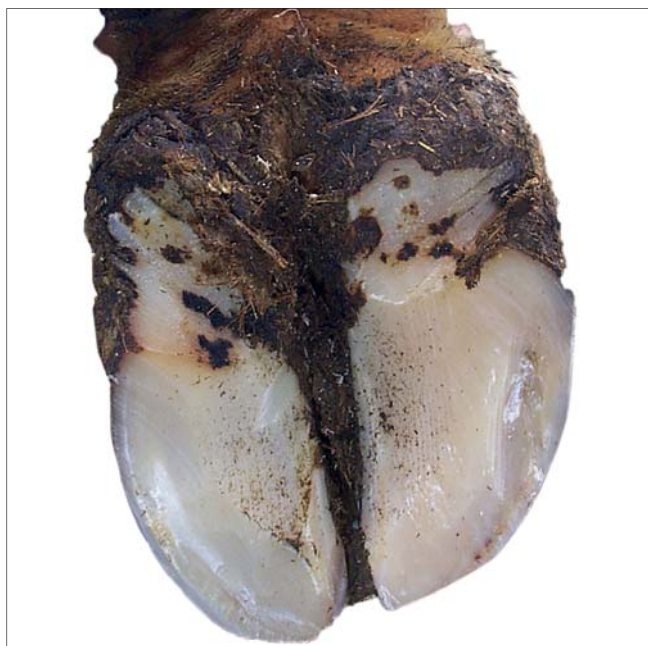
Heel horn erosion	Balleråd/ Balleforrådnelse	Kantasyöpymä	Hornforråtnelse	Klövröta	4
Sole haemorrhage	Såleblødning	Vertymiä anturassa	Blødning i sålen	Sulblødning	5
Sole ulcer	Sålesår	Anturahaavauma	Såleknusning	Klövsulesår	6
White line fissure	Hul væg, løs hvid linje	Valkoviivan repeämä	Løsning i den hvite linjen	Hålvægg, separation vita linjen	7
White line abscess/ White line ulcer	Hul væg, byld i hvid linje	Valkoviivan paise	Byll i den hvite linjen	Sår, böld i vita linjen	8
Interdigital hyperplasia/ Interdigital fibroma	Nydannelse	Sorkkavälin liikakasvu	Limax	Limax	9
Double sole	Dobbelt sål	Kaksoispohja	Dobbeltsåle	Dubbelsula	10
Dermatitis/ Skin infection	Hudbetændelse	Sorkkavälin ihotulehdus	Mild hudbetennelse (interdigital dermatitt)	Dermatit lindrig	11
Digital dermatitis	Digital dermatitis, DD	Sorkka-alueen ihotulehdus	Digital dermatitt	Digital dermatit	12
Verrucose dermatitis/ Wart growth/ Papillomatous digital dermatitis	Digital Vorte	Sorkkasyylä	Vorte	Vårta	13
Interdigital phlegmone/ Foul in the foot/ Foot rot	Klovbrandbyld	Sorkkavälin ajotulehdus	Klauvspalteflegmone	Klövspalts- inflammation	14
Toe ulcer/ Toe abscess	Tånekrose	Kärkipaise	Tåbyll	Tåböld	15
Asymmetric claws/ Different sized claws	Asymmetrisk klov	Epäsymmetriset sorkat	Asymmetriske klauver	Asymmetrisk klövform	16
Corkscrew claw	Proptrækker klov	Sorkkakiertymä/ Kierresorkka	Korketrekkerklauv	Korkskruvsklöv	17
Overgrown claws	Overgroet klov	Ylikasvaneet sorkat	Overvokste klauver	Förvuxen klöv	18
Scissor claws	Sakseklöv	Saksisorkat	Sakseklauver	Saxklöv	19
Chronic laminitis/ Laminitic ring	Snabelklov/ Laminitis vækstring	Krooninen sorkkakuume	Kronisk forfangenhet	Fångbrytning, konkav tåvägg	20
Lameness	Halthed	Ontuminen	Halthet	Hälta	21
Hock lesion	Hasetrykning	Kinnerhiertymä	Haseskade	Hasskada	22

Heel horn erosion

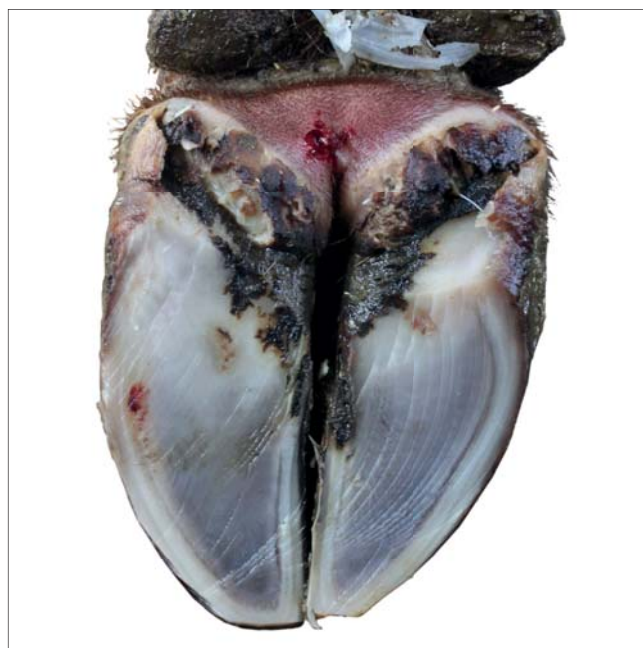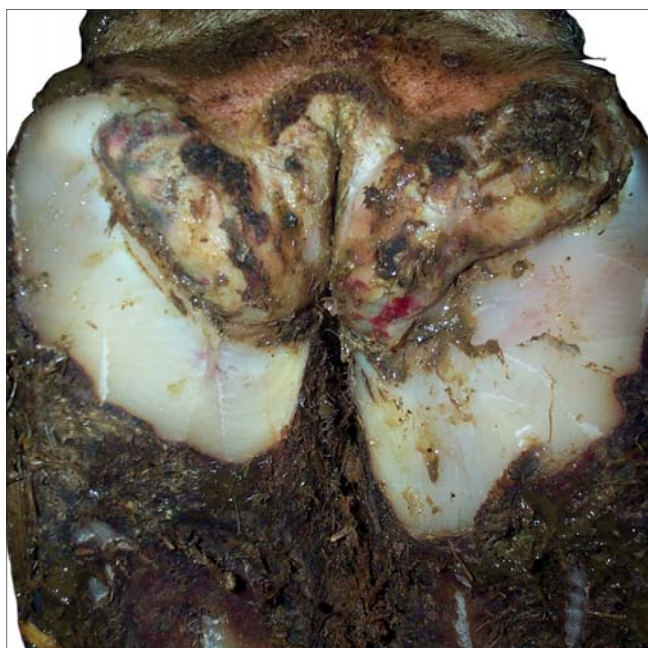-  Balleråd/
Balleforrådnelse
-  Kantasyöpymä
-  Hornforråtnelse
-  Klövröta

Mild



Superficial erosions of the bulbs.


Severe




Moderate to profound erosions of the bulbs, typical V-shaped, possibly extending to the corium.

Sole haemorrhage

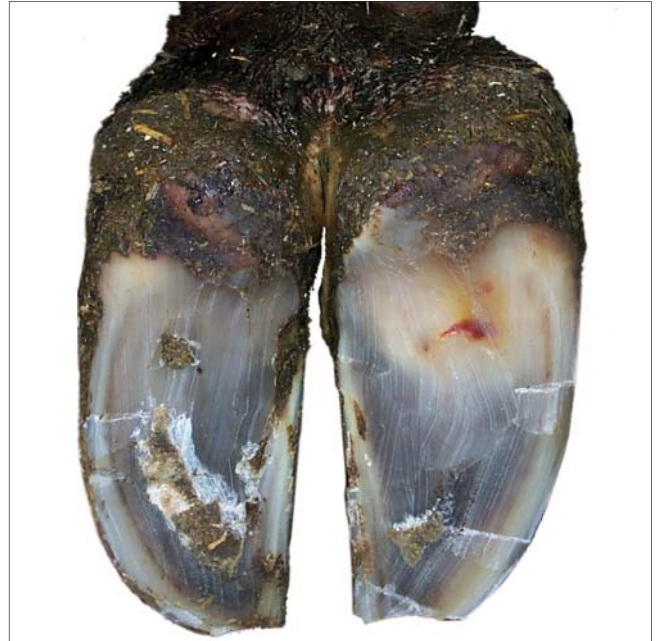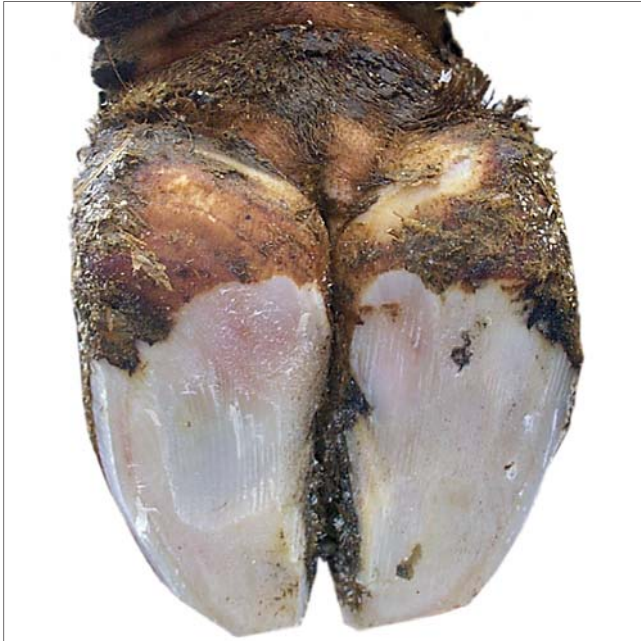 Såleblødning

 Vertymiä anturassa

 Blødning i sålen

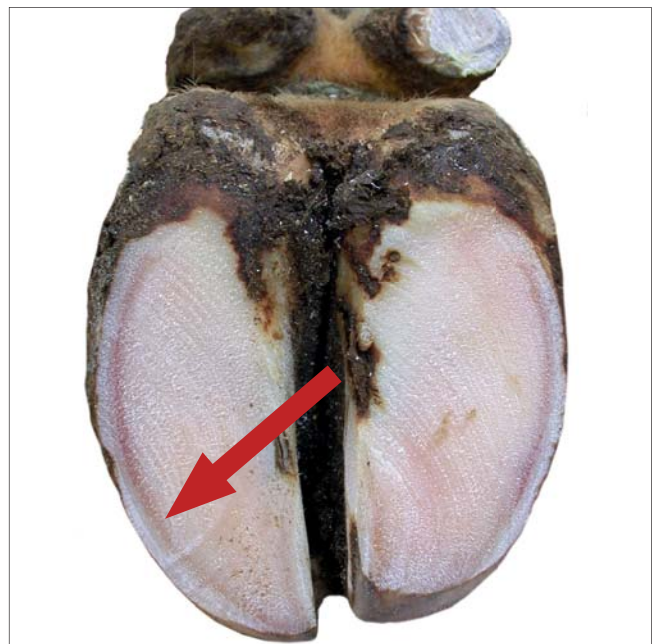
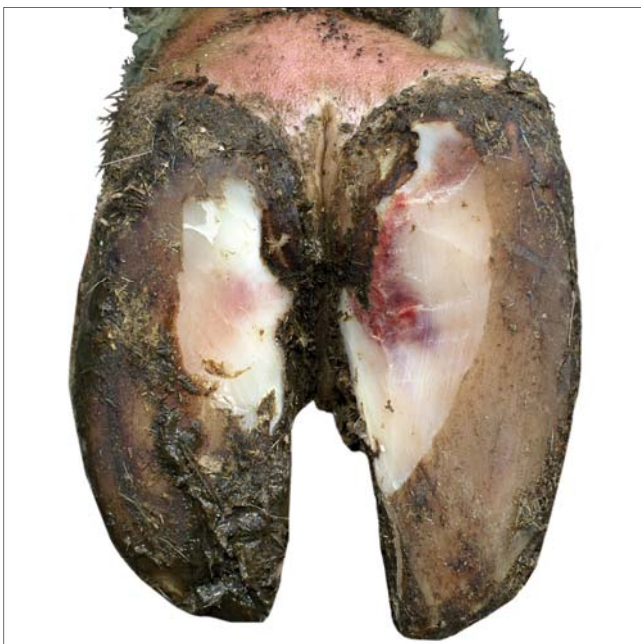
 Sulblødning

Mild



Superficial haemorrhage or slight discoloration of the horn of the sole and/or the white line, may disappear at normal trimming.

Severe

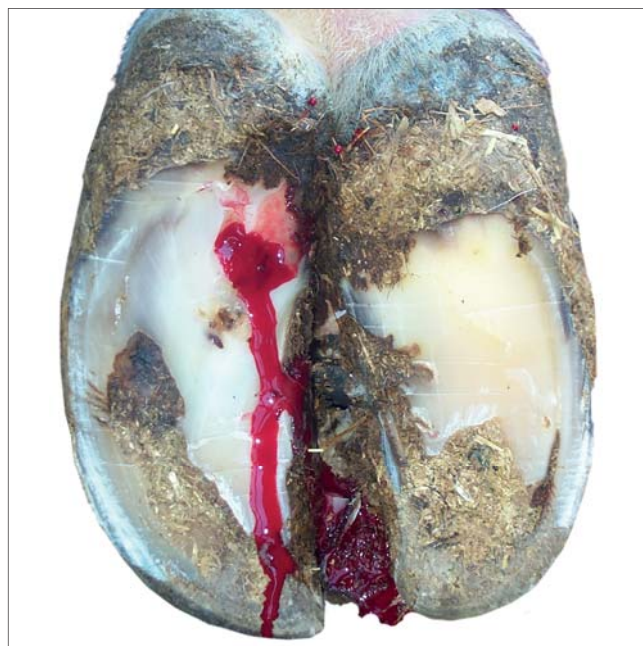
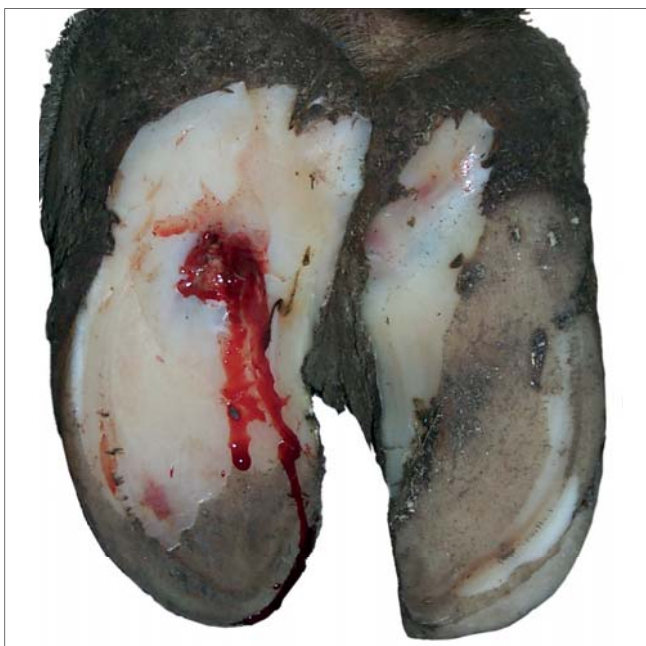

Profound haemorrhage of the horn of the sole and/or the white line, remains after trimming.

Sole ulcer

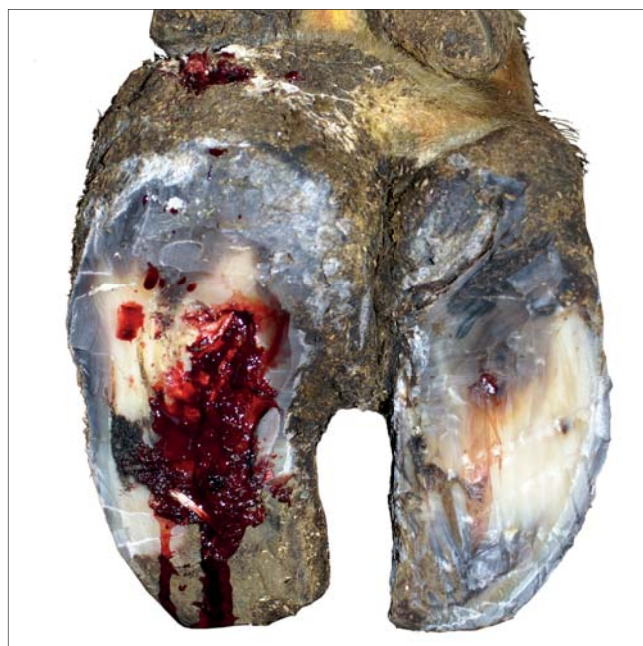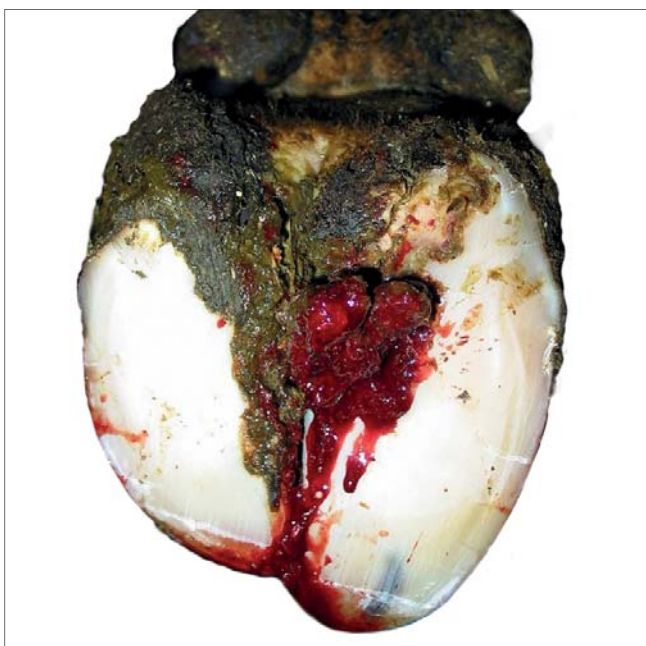-  Sålesår
-  Anturahaavauma
-  Såleknusning
-  Klövsulesår

Mild



Penetration through the sole horn exposing fresh corium. Located in the typical rear part of the sole.

Severe



Penetration through the sole horn exposing affected corium with necrotic miscoloured tissue and/or protruding granulation tissue. Located in the typical rear part of the sole.

White line fissure



Hul væg, løs hvid linje



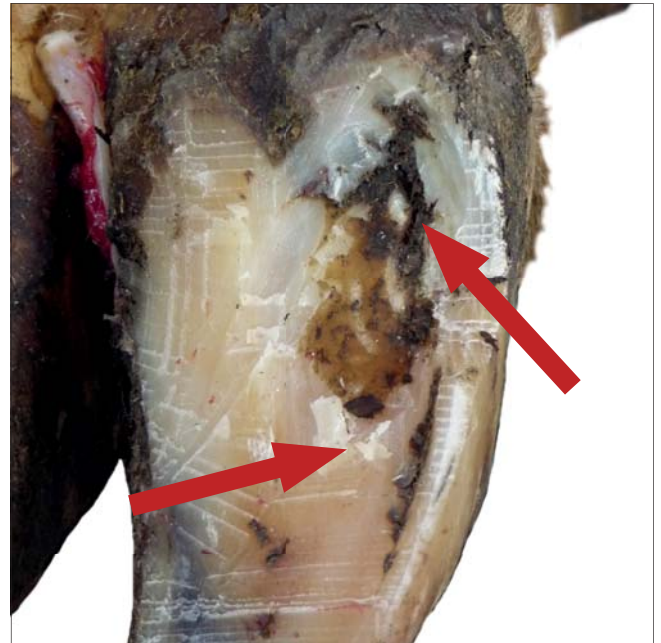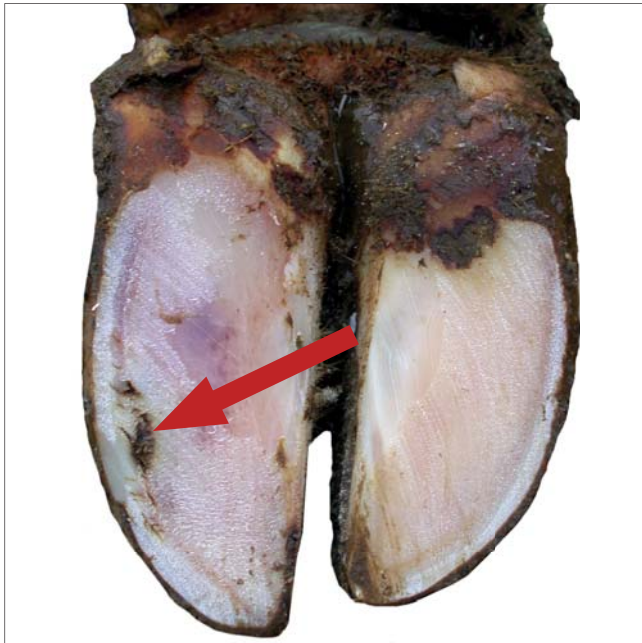
Valkoviivan repeämä



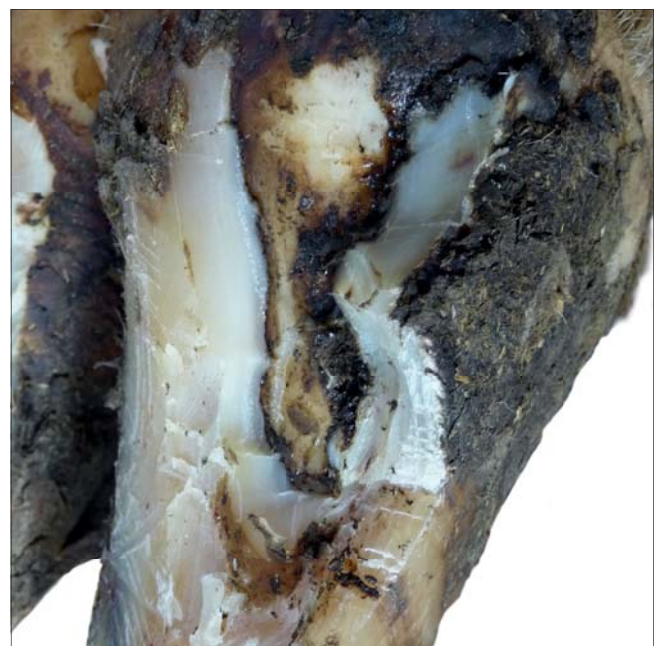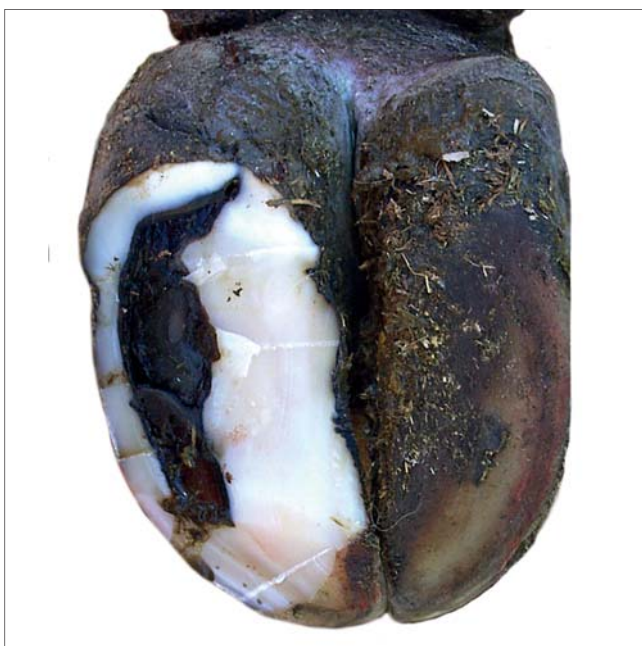Løsning i den hvite linjen



Hålvägg, separation vita linjen



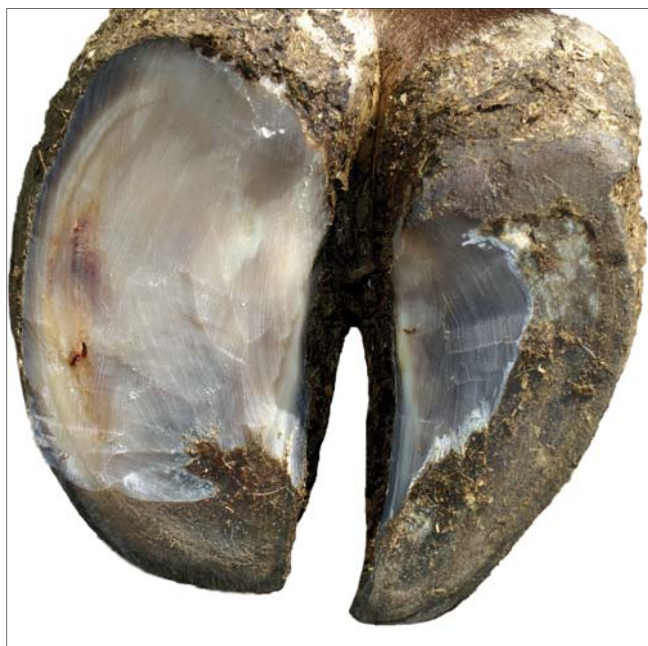
Separation of the white line, remains after normal trimming.



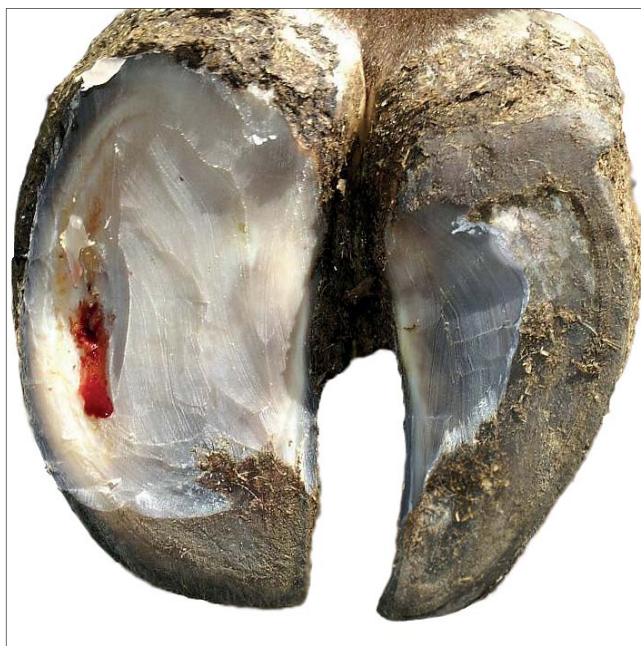White line abscess/ White line ulcer

-  Hul væg, byld i hvid linje
-  Valkoviivan paise
-  Byll i den hvite linjen
-  Sår, böld i vita linjen

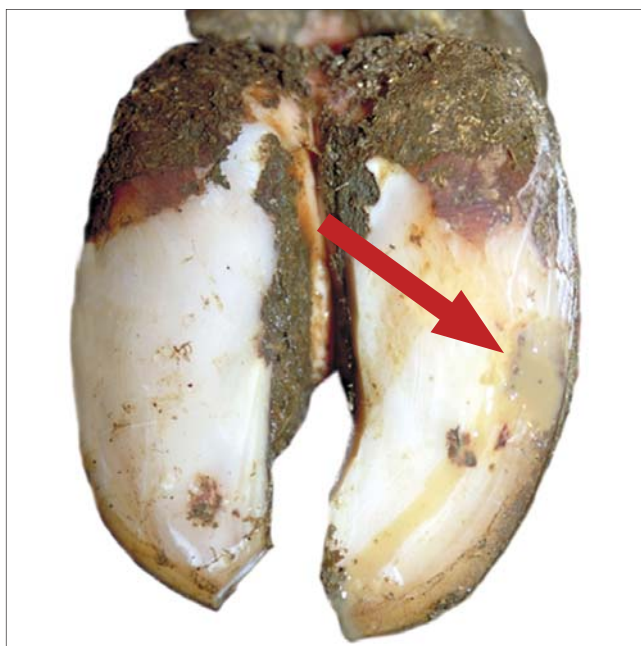
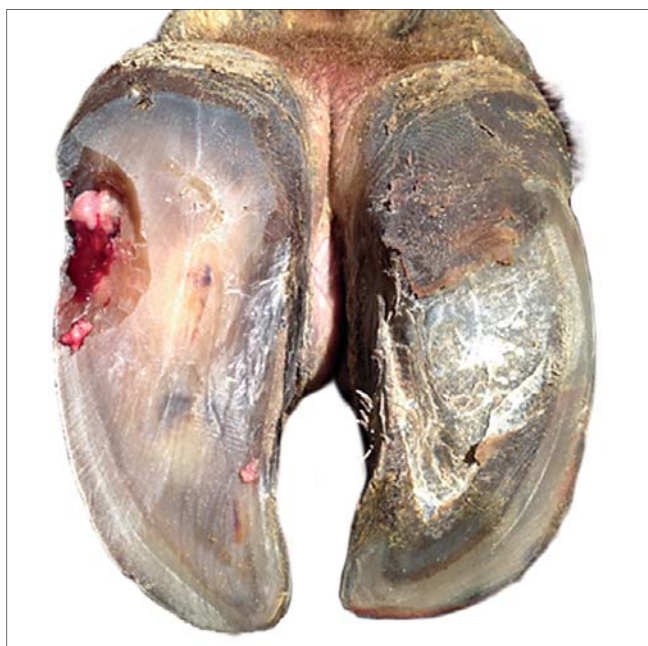Before opening



After opening



Exposed corium without purulent exudation originating from a fissure of the white line.



Exposed corium with purulent exudation originating from a fissure of the white line.

Interdigital hyperplasia/ Interdigital fibroma



Nydannelse



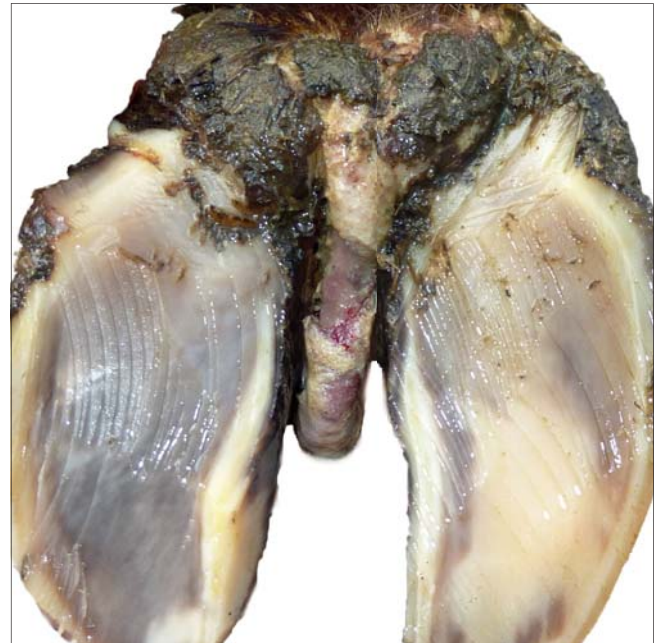
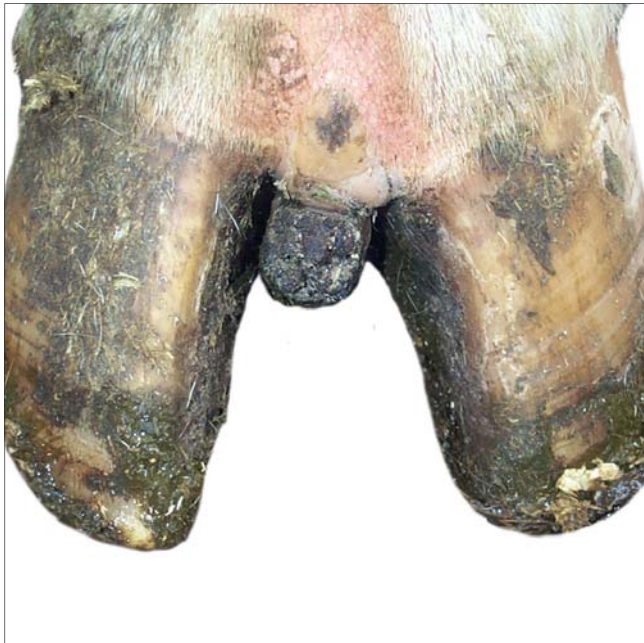
Sorkkävälin liikakasvu



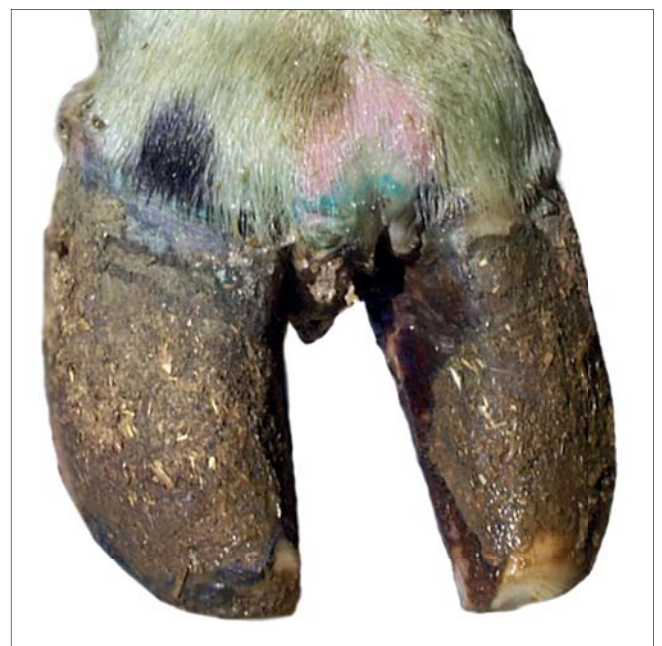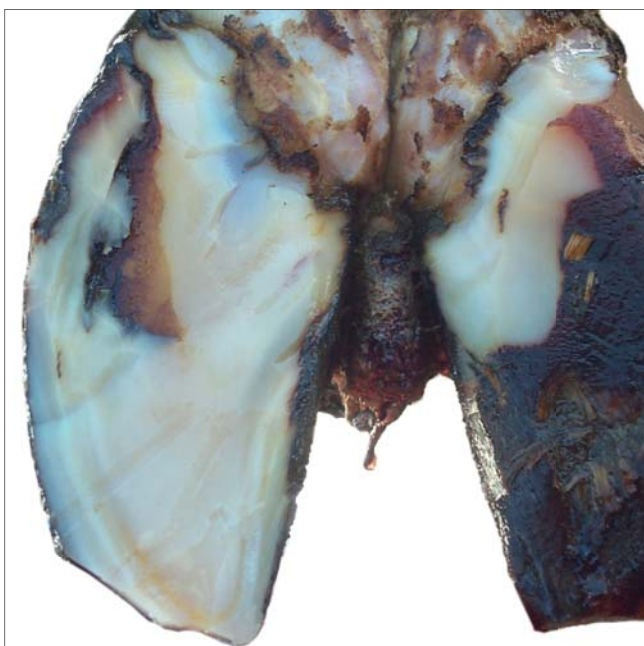
Limax



Limax

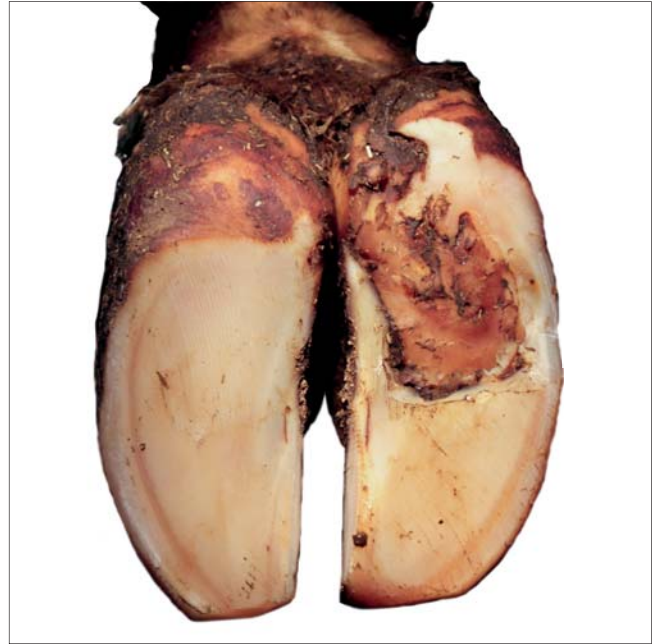
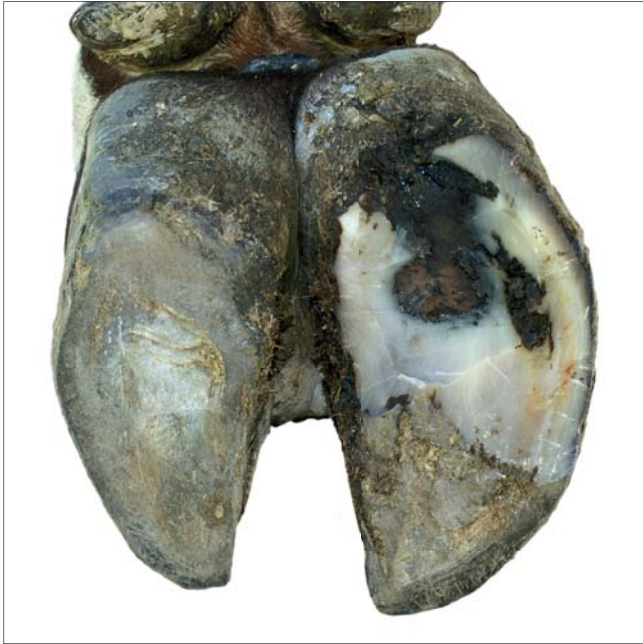
Interdigital growth of fibrous tissue.

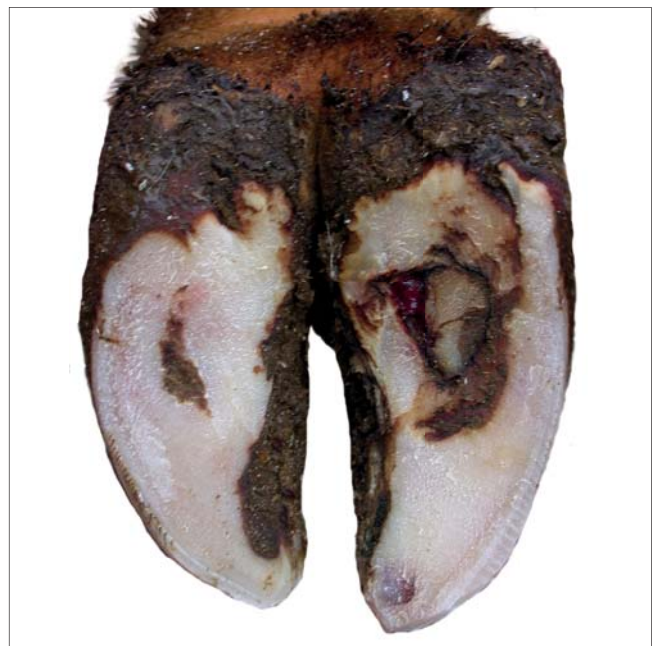
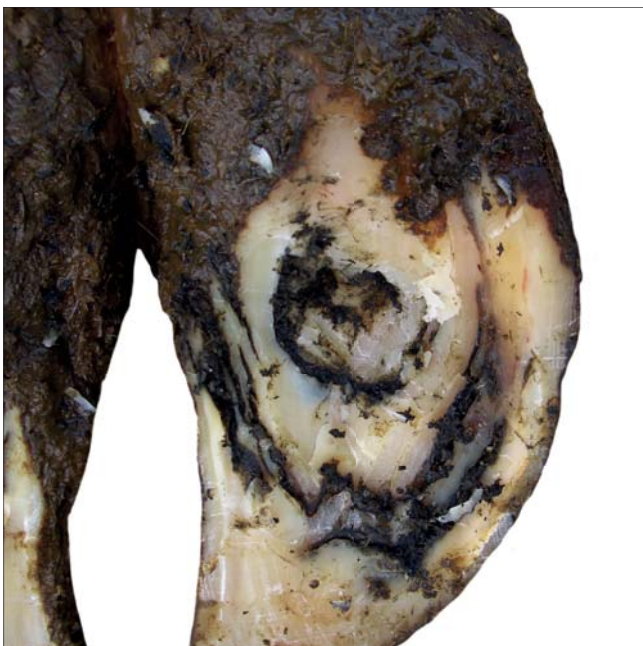
Double sole

-  Dobbelt sål
-  Kaksoisohja
-  Dobbeltsåle
-  Dubbelsula



Two or more layers of under-run sole horn.



Dermatitis/ Skin infection



Hudbetændelse



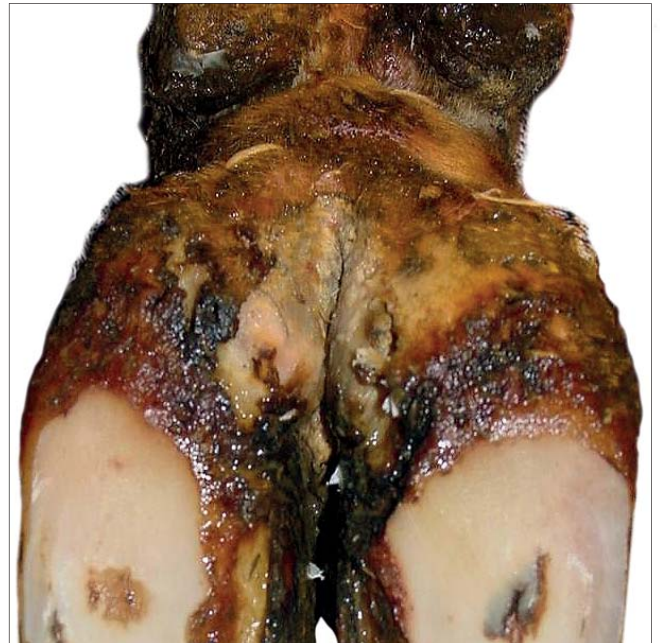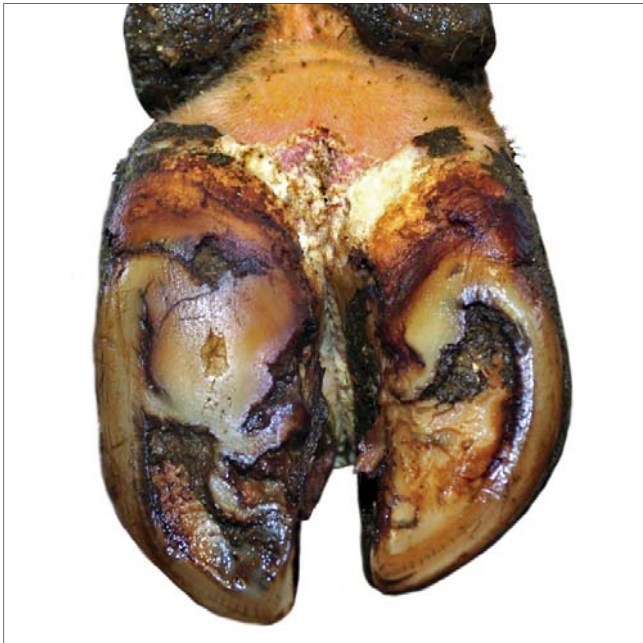Sorkkavälin ihotulehdus



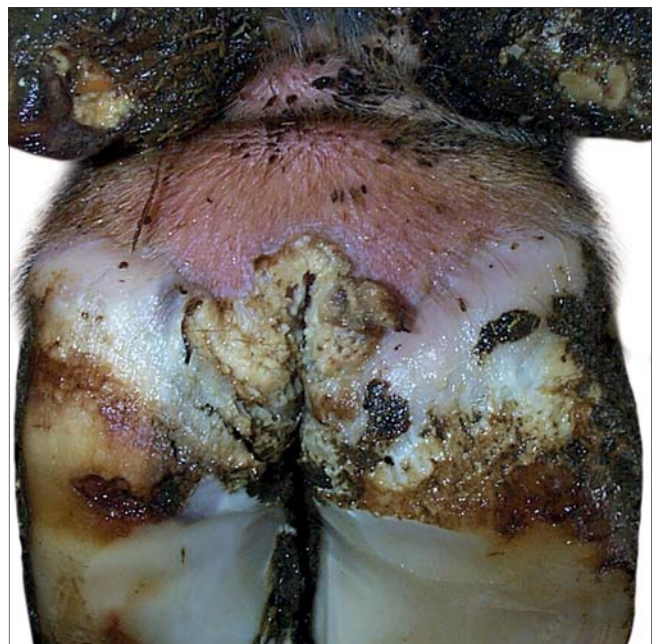
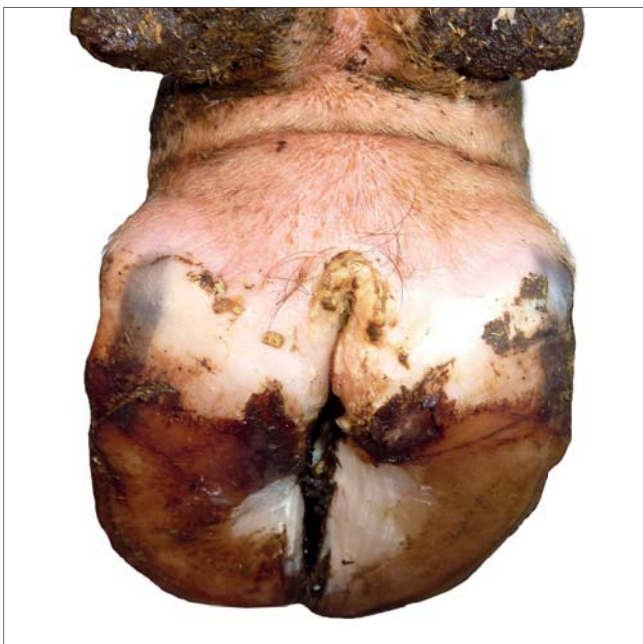
Mild hudbetennelse
(interdigital dermatitt)



Dermatit lindrig

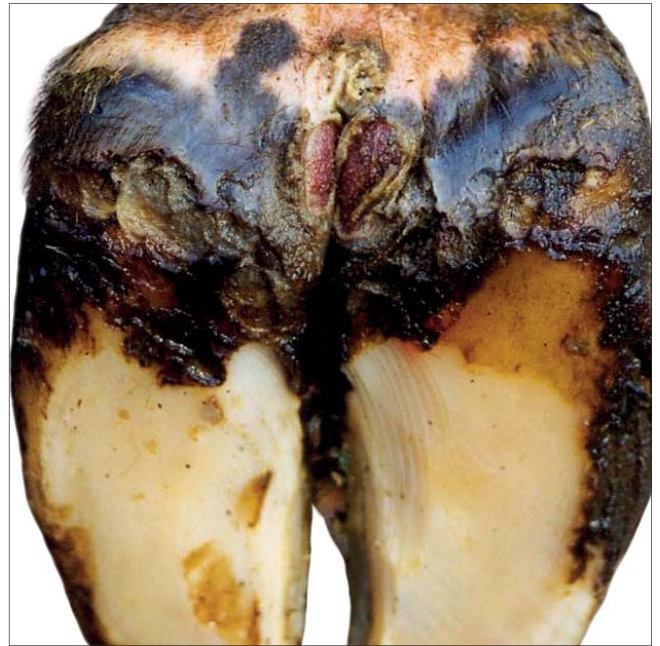
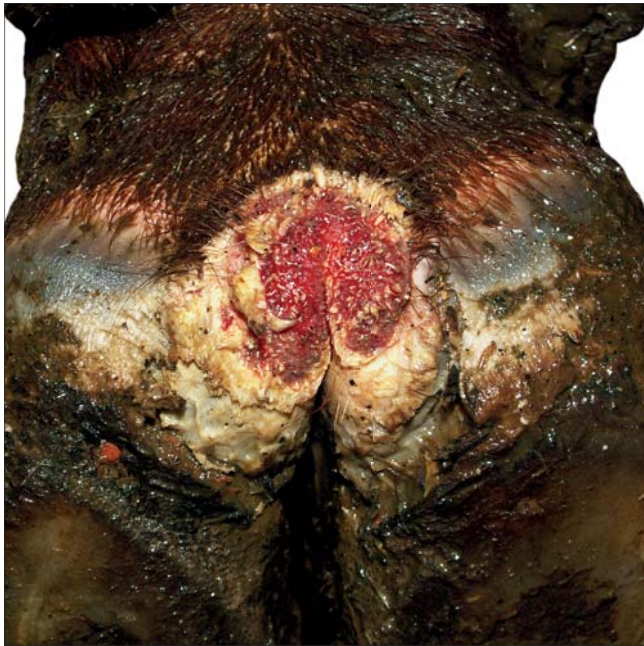
Infection of the digital and/or interdigital skin with exudation or dry crusts (hyperkeratosis). Not painful.

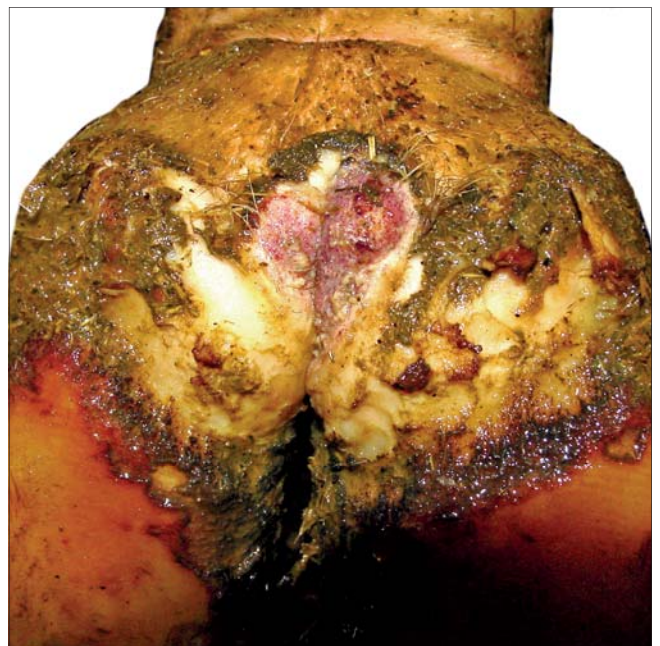
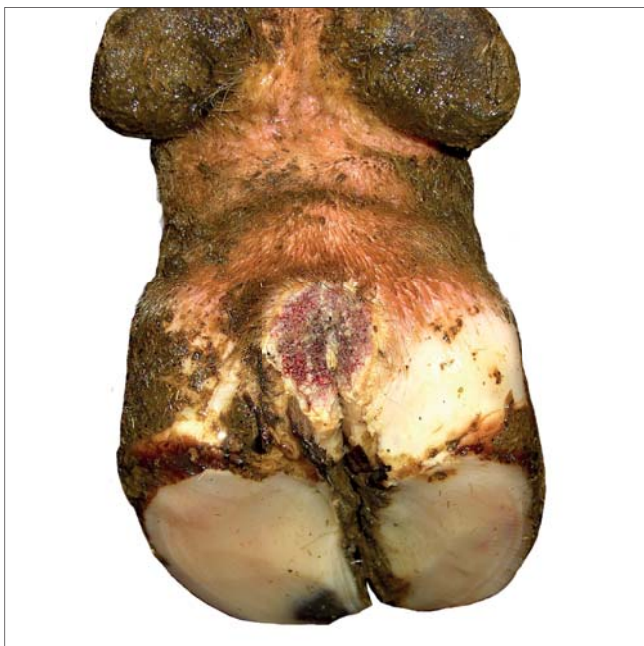

Digital dermatitis

-  Digital dermatitis, DD
-  Sorkka-alueen ihotulehdus
-  Digital dermatitt
-  Digital dermatit

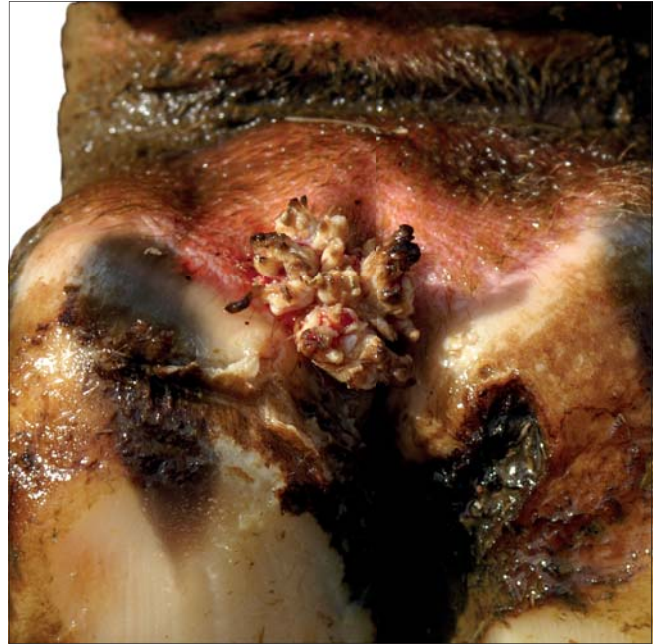
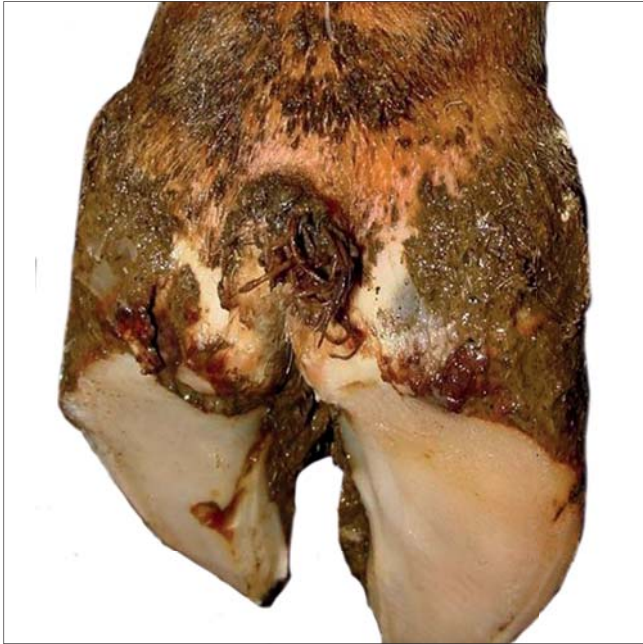

Infection of the digital and/or interdigital skin with erosion, bleeding ulcerations. Painful.

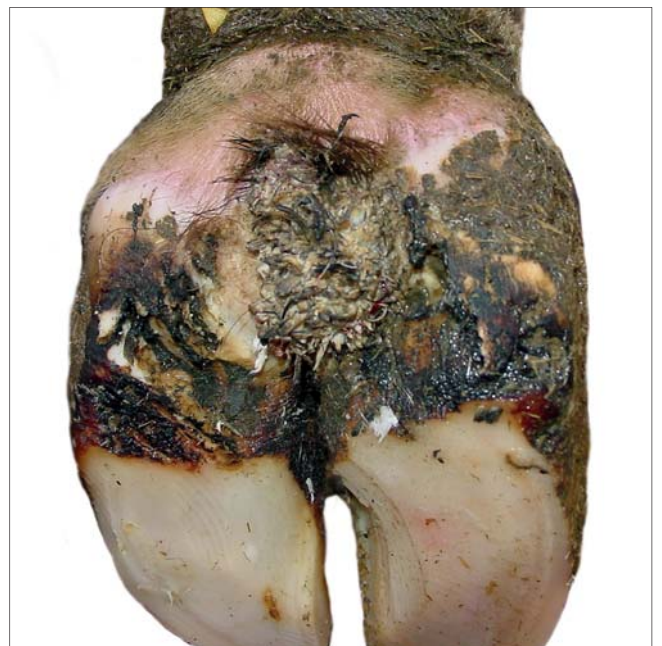
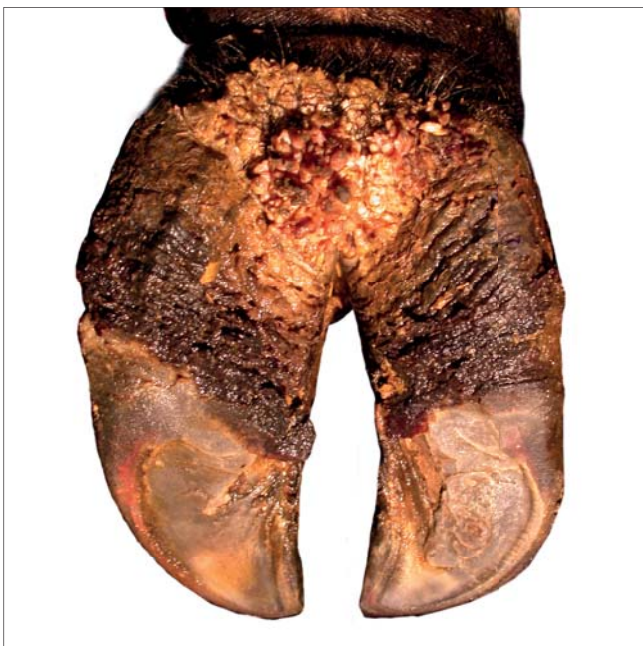
Verrucose dermatitis/ Wart growth/ Papillomatous digital dermatitis

-  Digital Vorte
-  Sorkkasyylä
-  Vorte
-  Vårta



Papillomatous dermatitis, often a chronic stage of digital dermatitis.



Interdigital phlegmone/ Foul in the foot/ Foot rot



Klovbrandbyld



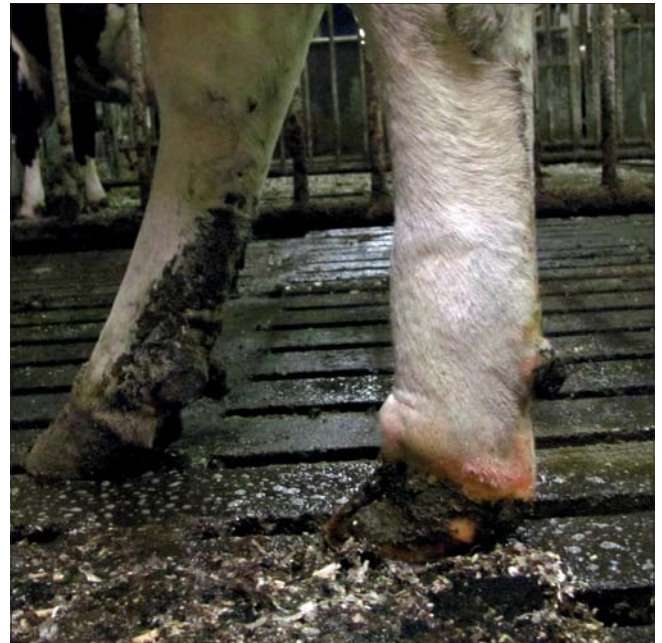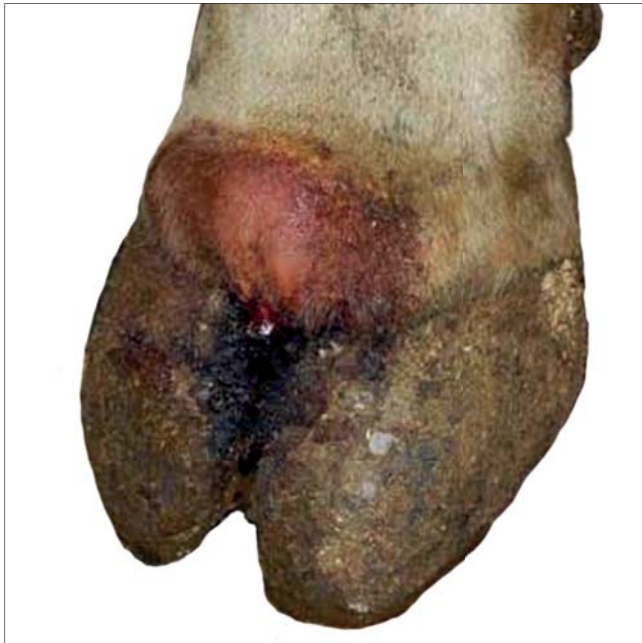Sorkkavälin ajotulehdus



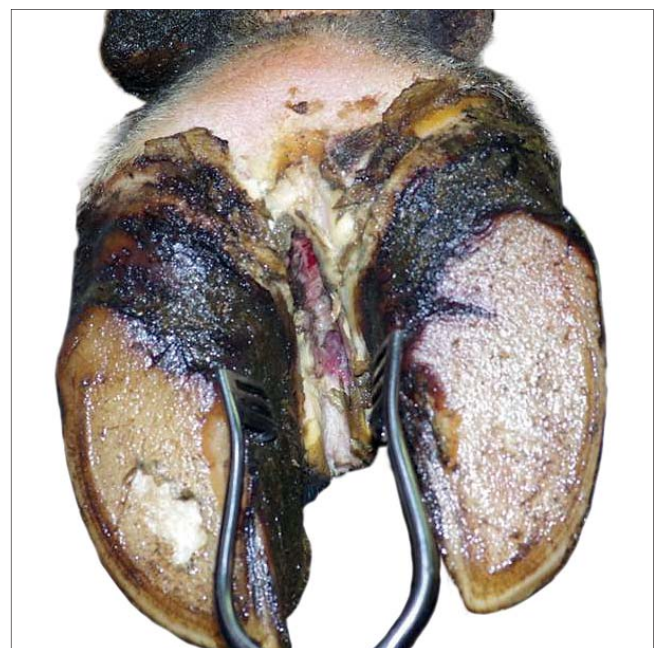
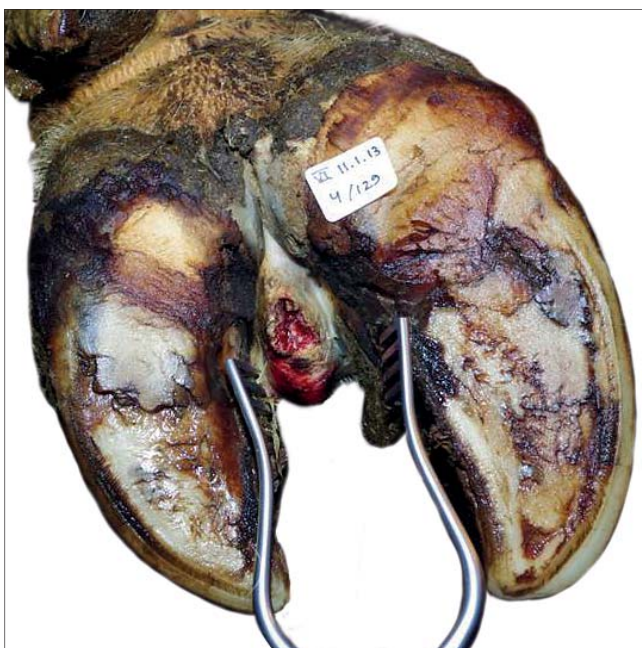
Klauvspaltesflegmone



Klövspaltsinflammation



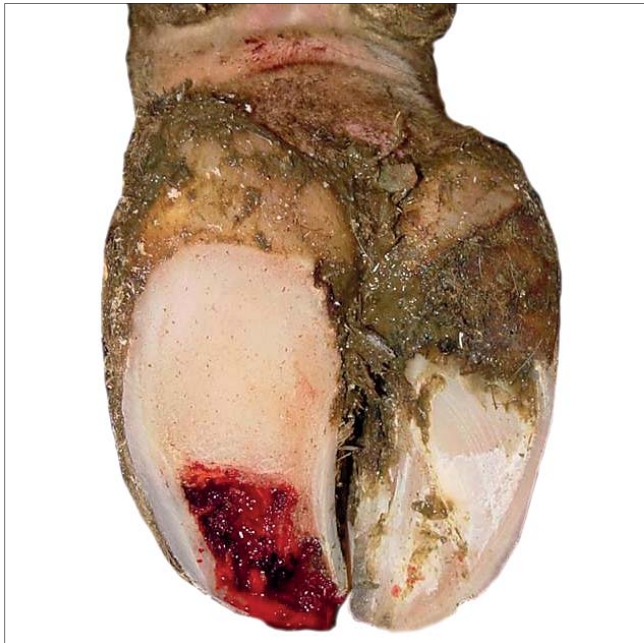
Deep interdigital infection with symmetric swelling of the foot, fever and lameness, often on only one foot.



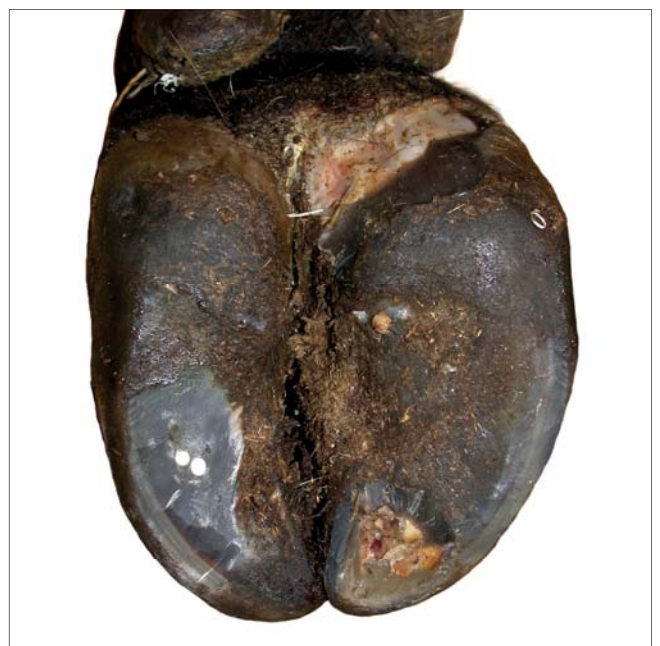
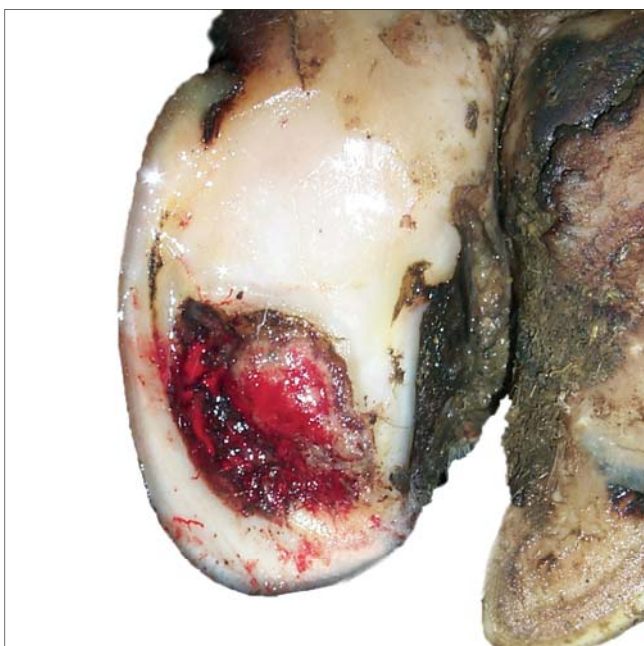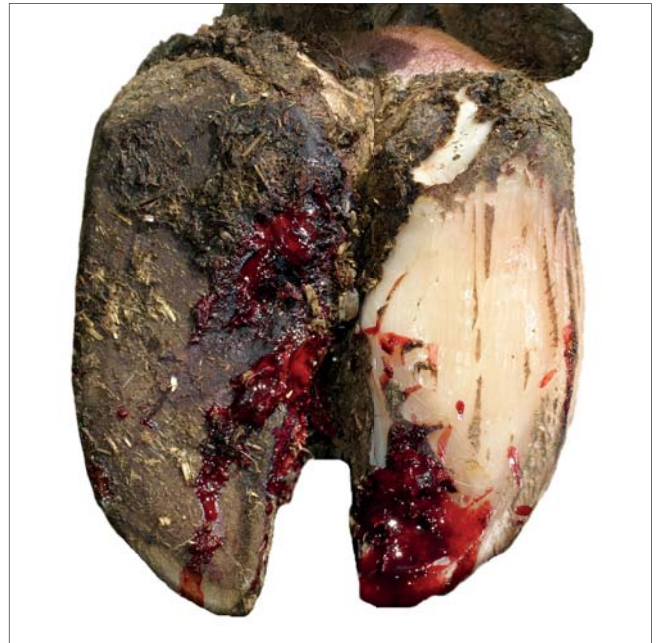Deep interdigital infection with swelling, odor, ulceration, commonly necrotic tissue.

Toe ulcer/ Toe abscess

-  Tånekrose
-  Kärkipaise
-  Tåbyll
-  Tåböld



Ulceration of toe with abscess and/or necrotic tissue.



Asymmetric claws/ Different sized claws



Asymmetrisk klov



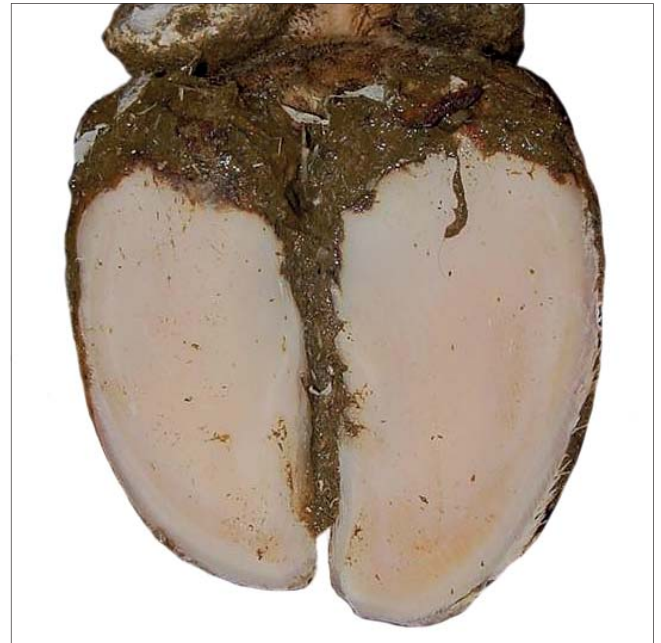
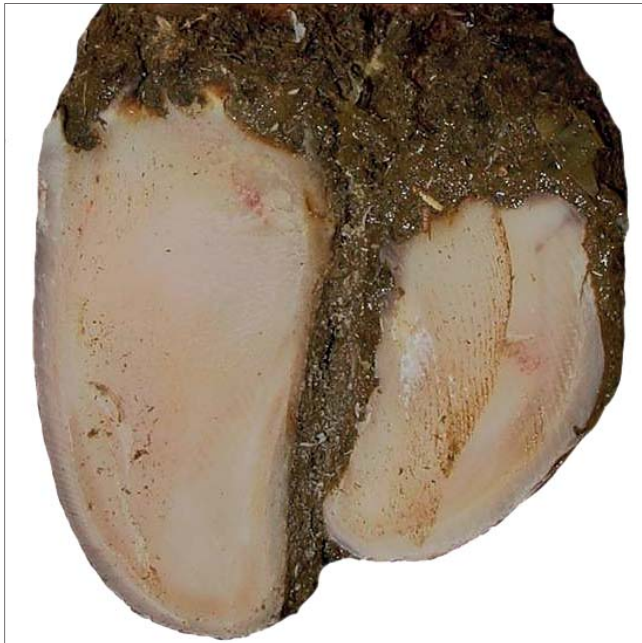Epäsymmetriset sorkat



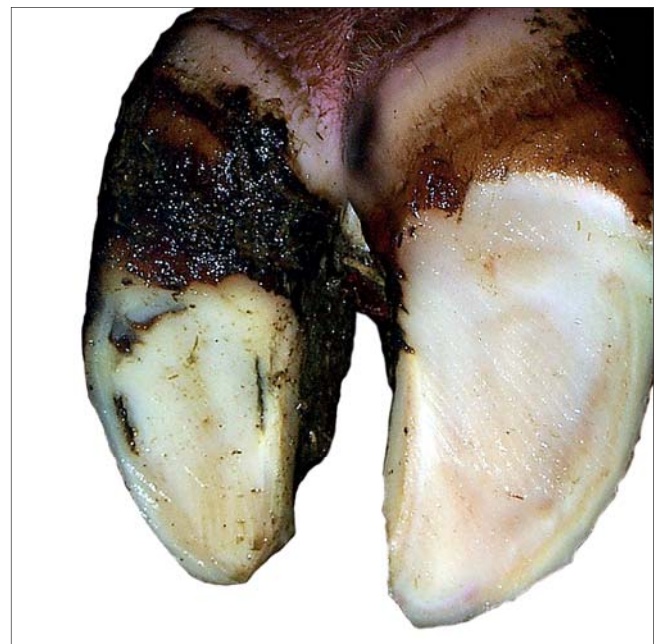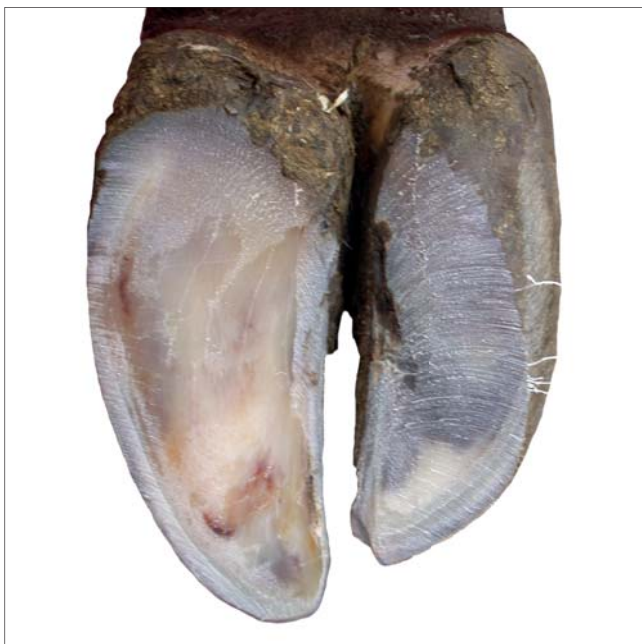Asymmetriske klauver



Asymmetrisk klövform

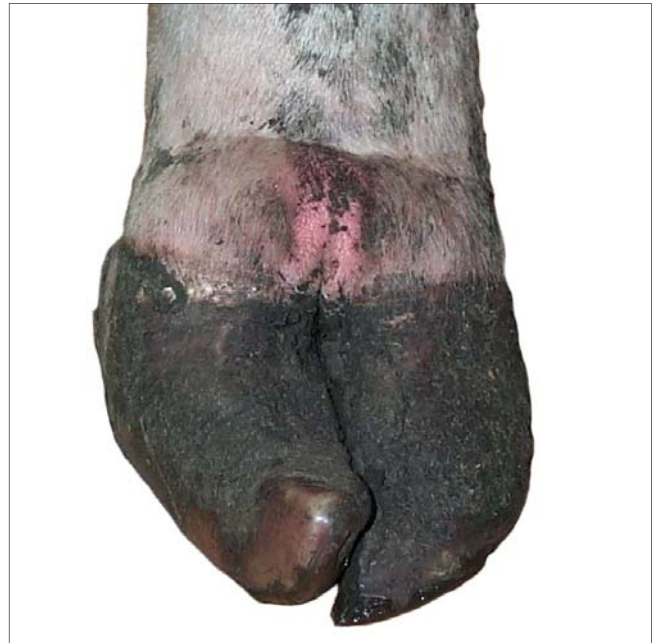
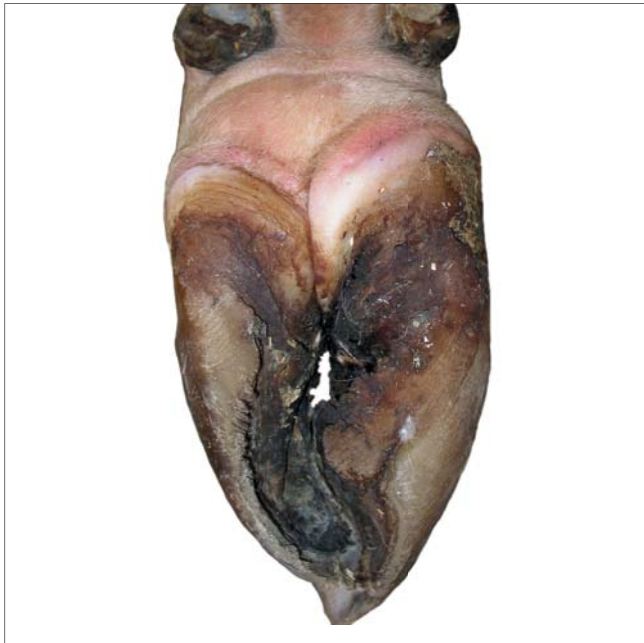
Significant difference in width, height and/or length between outer and inner claw.

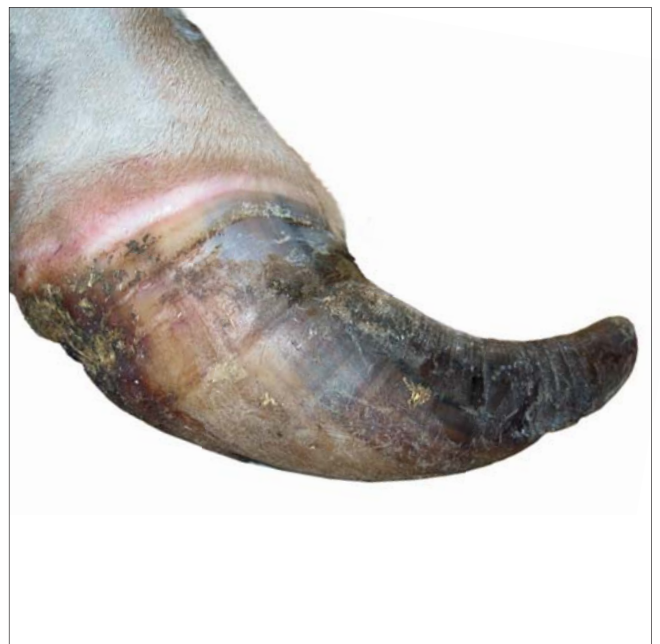
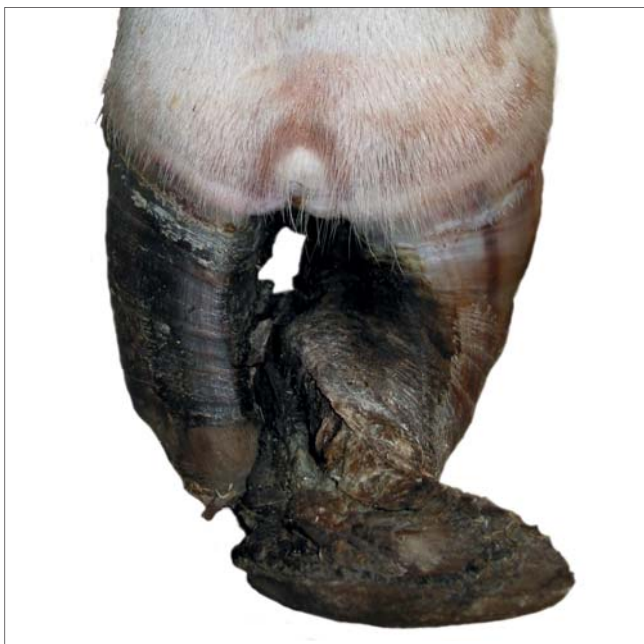
Corkscrew claw


-  Proptrækker klov
-  Sorkkakiertymä/
Kierresorkka
-  Korketrekkerklauv
-  Korkskruvsklöv





Any inward torsion lengthwise of the either outer or inner claw. The dorsal edge of the wall deviates from a straight line.



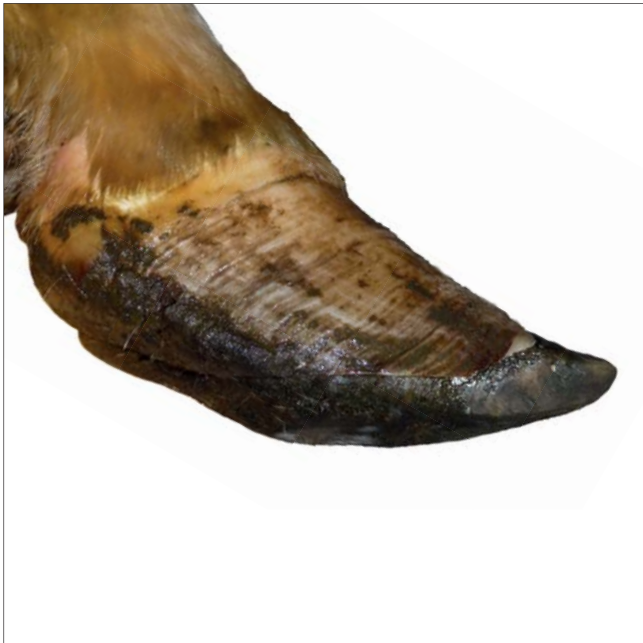Overgrown claws

 Overgroet klov

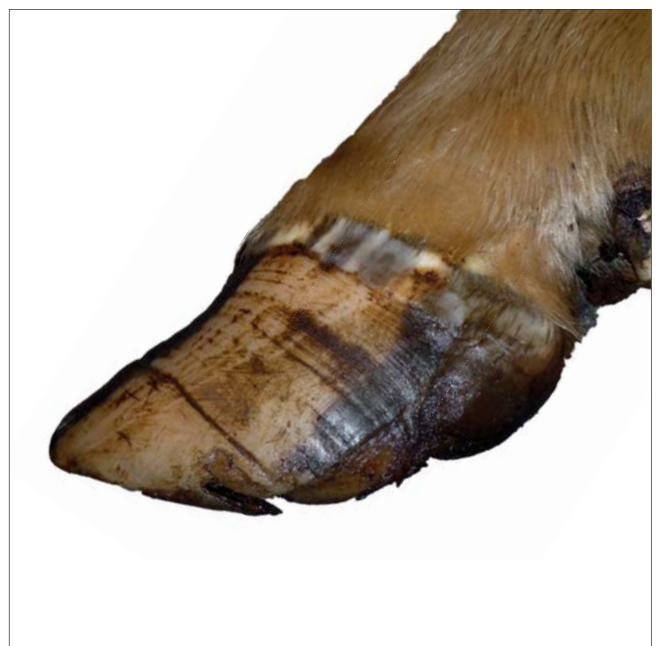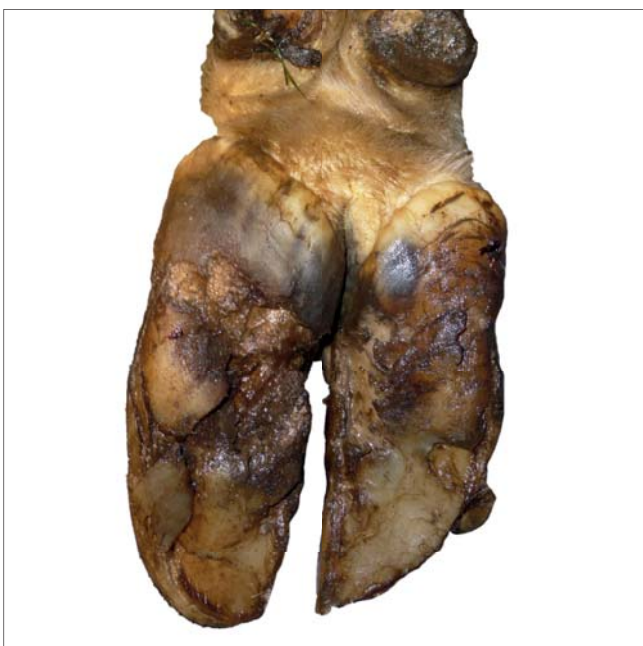
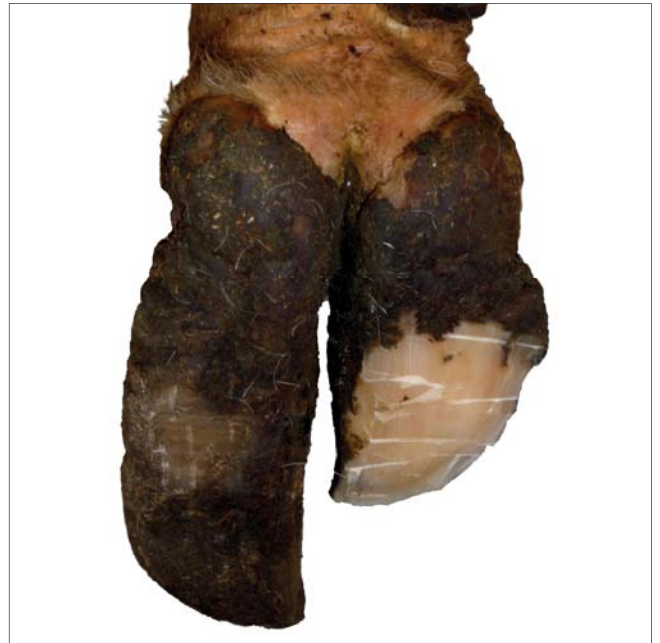 Ylikasvaneet sorkat

 Övervokste klauver

 Förvuxen klöv

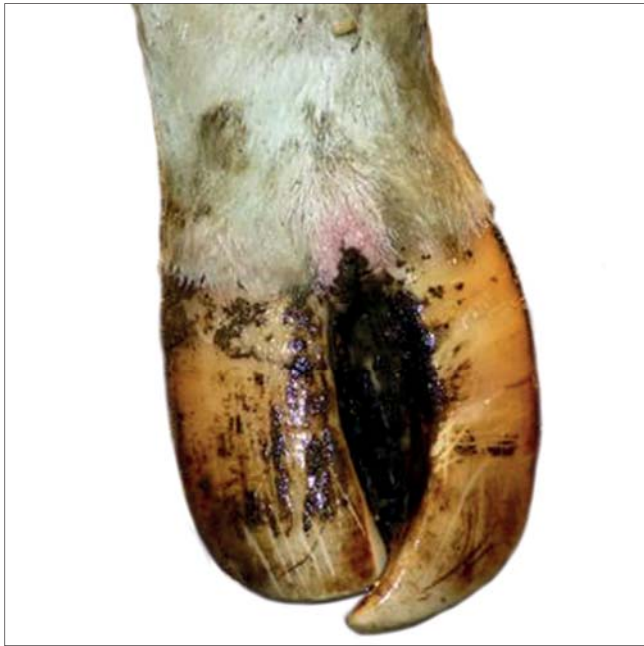

Severely overgrown toes (>100 mm).

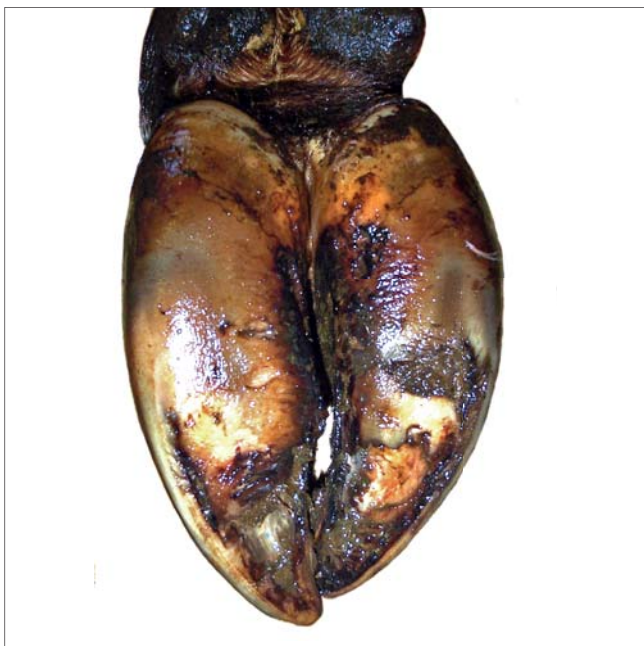
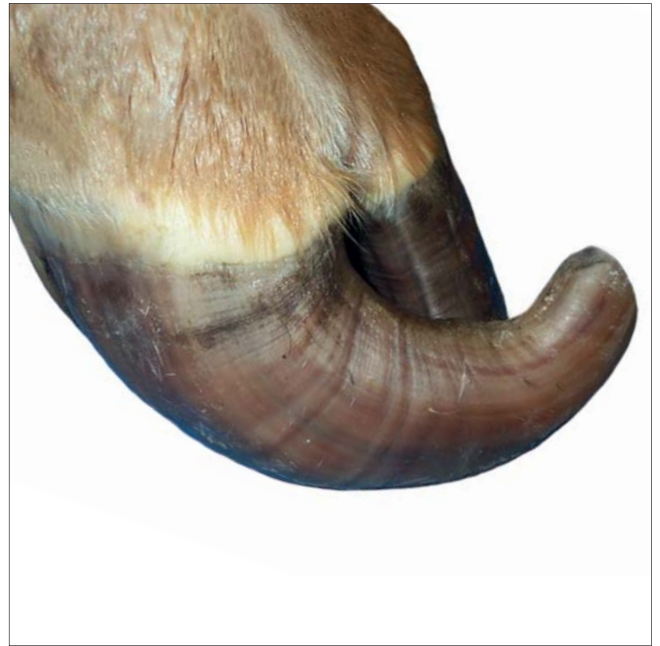
Scissor claws


-  Sakseklov
-  Saksisorkat
-  Sakseklauber
-  Saxklöv





Tip of toes crossing each other.




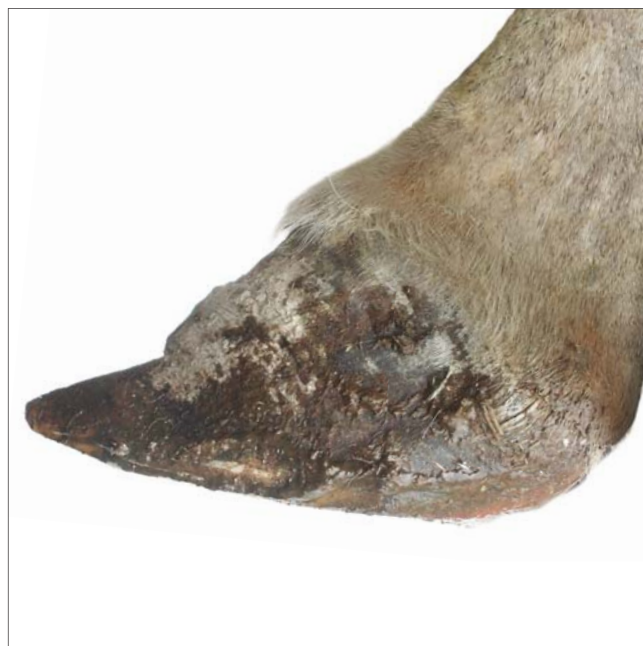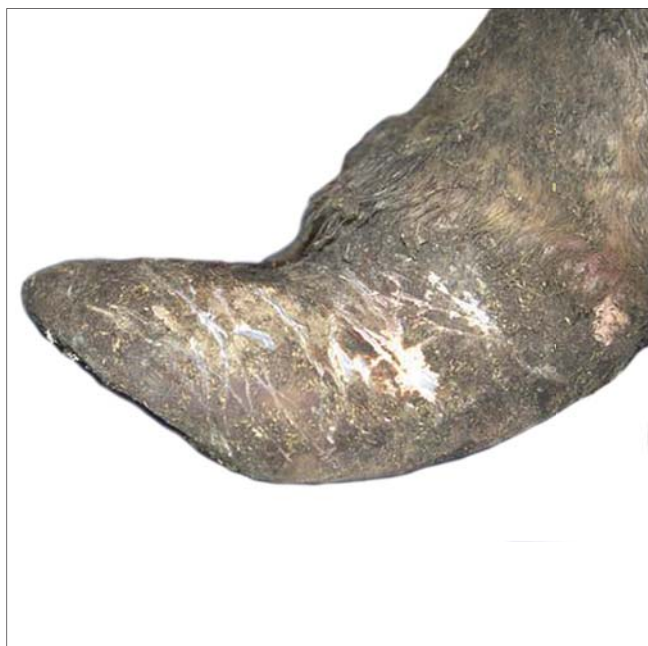Chronic laminitis/ Laminitic ring

 Snabelklov/
Laminitis vækstring

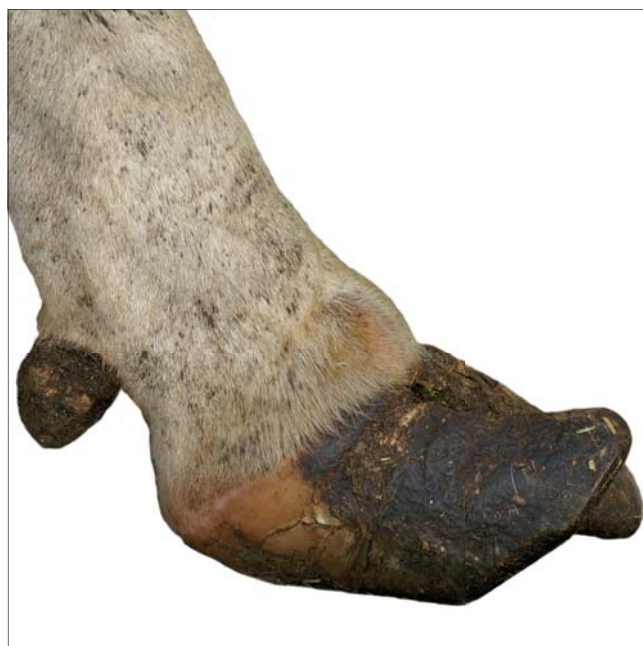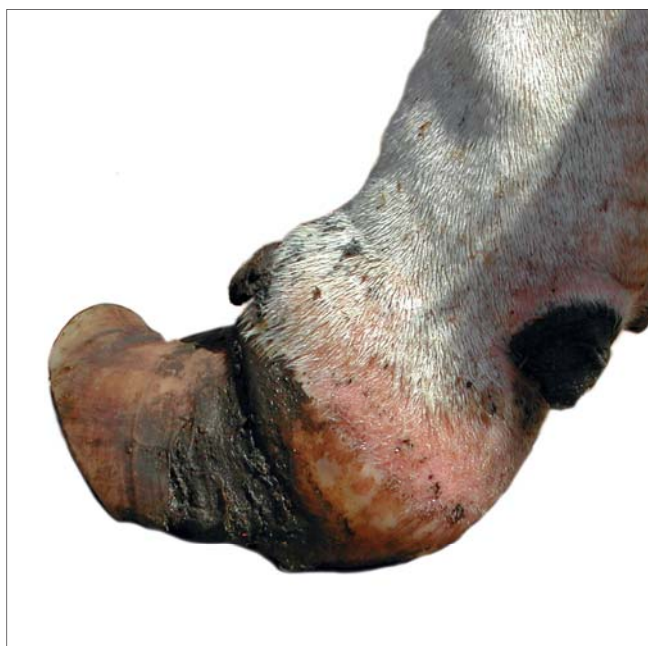 Krooninen
sorkkakuume

 Kronisk forfangenhet

 Fångbrytning, konkav
tåvägg



Concave deviation of the dorsal wall with horizontal line(s) i.e. laminitic ring(s).



Lameness

-  Halthed
-  Ontuminen
-  Haltet
-  Hälta

Mild



Stands normal but walks with an arched back and with stiffness.

Severe



Stands and walks with an arched back and is clearly lame, nodding of the head.

Hock lesion

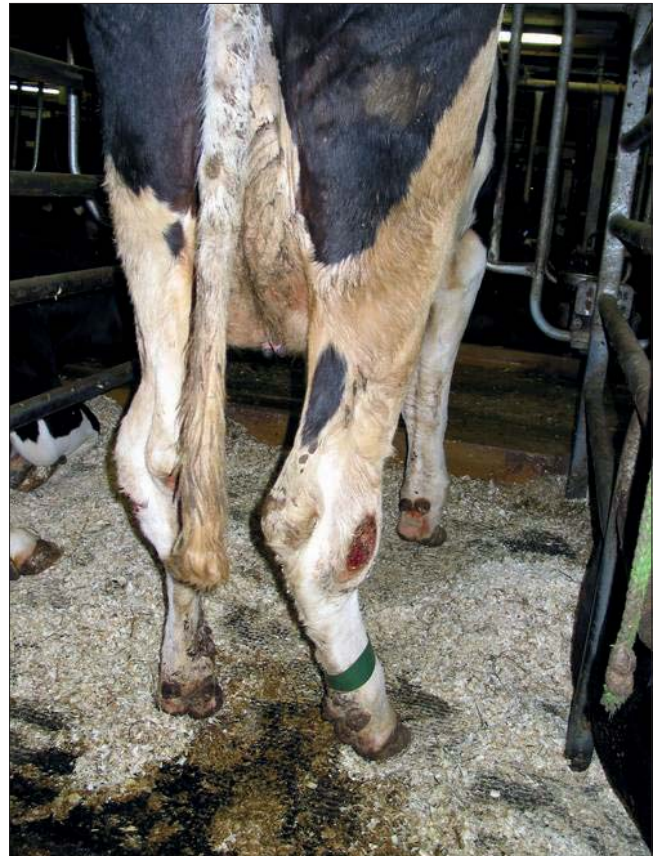-  Hasetrykning
-  Kinnerhiertymä
-  Haseskade
-  Hasskada

Mild



Swollen hock with superficial decubital injury.

Severe



Swollen hock with ulcer.

A pdf of the Nordic Claw Atlas is available to download from the following websites:

www.sundklov.dk

www.faba.fi

<http://storfehelse.no>

www.vxa.se

